

## Donkey Foot Care – Notes for Farriers

### The normal donkey foot

- \* Hoof pastern axis is broken forward compared to the horse (between 5° and 10° more).
- \* Hoof walls are more upright compared to the horse.
- \* The frog is smaller and set further back compared to the horse frog.
- \* The sole has a “U” shape with a flare to the heels compared to the rounder shape of a horse's hoof.
- \* The wall is a consistent thickness around the hoof, compared to the horse's hoof where the thickness tapers.
- \* White line should be ~1mm wide.
- \* If any wider may indicate white line disease or laminitis.
- \* Sole grows nearly as much as the walls.
- \* Heels grow faster relative to toe growth.
- \* Adapted to dry climates, they have a higher water content and are more “elastic” than horse hooves.

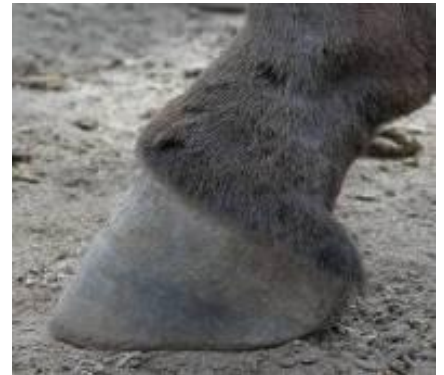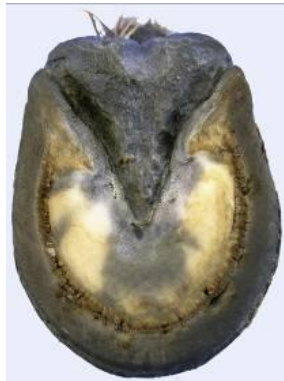### Trimming the normal foot

Trim every 6 – 10 weeks as required.

Due to size or arthritic changes, they may resent lifting of limbs– you may have to go down to their level and handle their hooves as low to the ground as possible.

#### Tools

Your normal farrier kit +  
Half round nippers  
Loop knife  
Short bladed knife  
Coarse rasp



#### Sole

Remove any loose or unhealthy material.

Trim frog to a tidy “V” shape.

Pare sole so that it is concave and gives slightly with firm thumb pressure.

#### Wall

Avoid excessive rasping of the outer layers; however they can be bevelled with a rasp to prevent splitting.

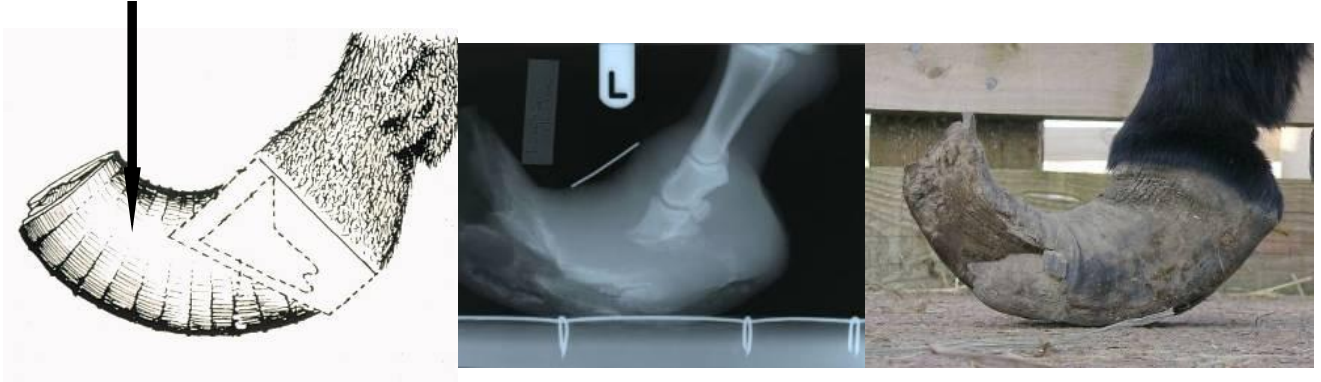The point of the frog or mid-point of the sole should be approx 6mm (¼ in) above the wall so that the walls are weight bearing – not the sole.

## Trimming the overgrown foot

The overgrown foot may rock back onto the heels resulting in a “Turkish slipper” appearance.

Flexor tendons and joints may be under more stress. The pedal bone usually stays in the same place relative to the coronary band, X-rays can confirm this and overgrown horn can then be removed.

Hoof tissue to be removed

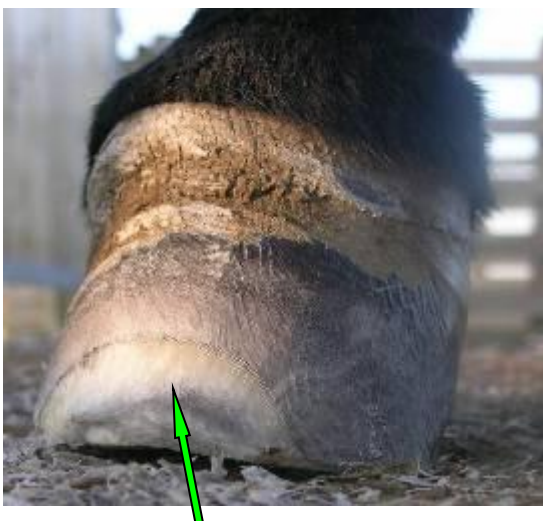


Clean, trim and shape frog and sole first. Trim hoof wall starting at the heels.

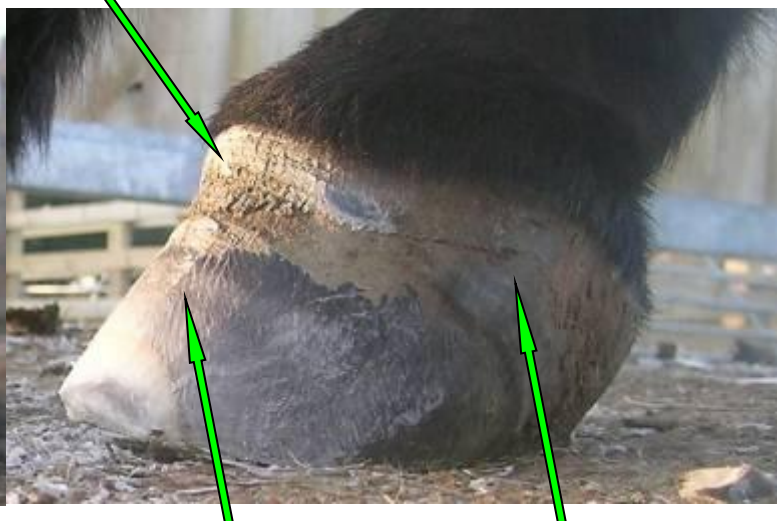When shaping the hoof bear in mind the position of the pedal bone.



A finger's width of horn at the top of the coronary band can be used as a guide for the angle of the front surface of the hoof wall.



Outer hoof wall rasped back



Rasped hoof wall

Untouched hoof wall

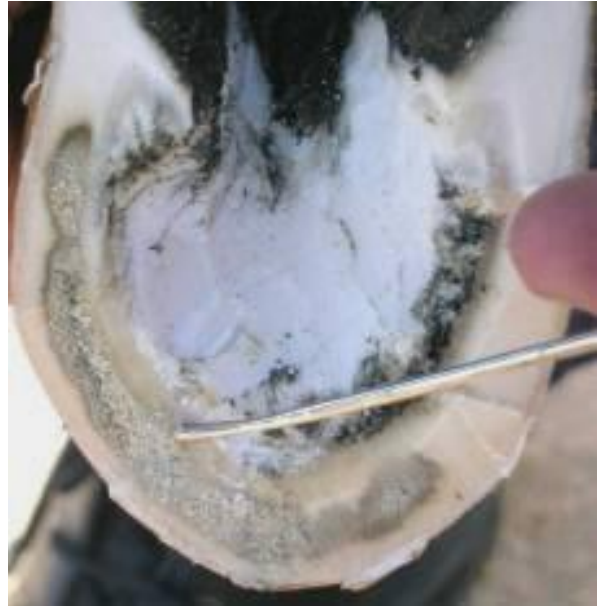All the above images are of the same donkey foot.

© The Donkey Sanctuary 2009

## Seedy Toe – Notes for Farriers

The affected horn has a grey crumbly texture with lesions varying in severity from minor slits in the hoof wall to extensive cavities with separation of the wall from the white line. Seedy toe lesions are rarely painful unless there is extensive hoof instability, but the widened white line may allow entry of organisms and subsequent abscess formation.

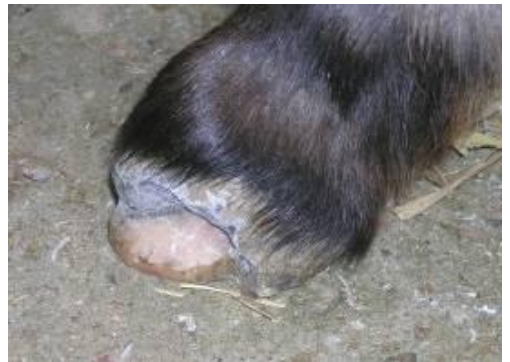In severe cases the farrier should work with a veterinarian.



**All necrotic and discoloured material should be removed to expose clean, healthy horn.**

It is possible to resect high up the hoof wall (more so than in the horse), to remove all the affected material. Exposure is necessary to provide an aerobic environment which inhibits bacterial and fungal colonisation.

If extensive resection is necessary X-rays should be taken first to check for any laminitic changes that might affect the stability of P3.



“Sugardine” is a cheap and effective dressing with a fungicidal and antibacterial action, and promotes the drying and hardening of the exposed hoof. It may need to be applied for a couple of days after resection to harden the remaining hoof. Apply to the affected hoof and keep in place with a thick cotton wool pad, cohesive-type bandage & silage bag patches to waterproof the bandage.

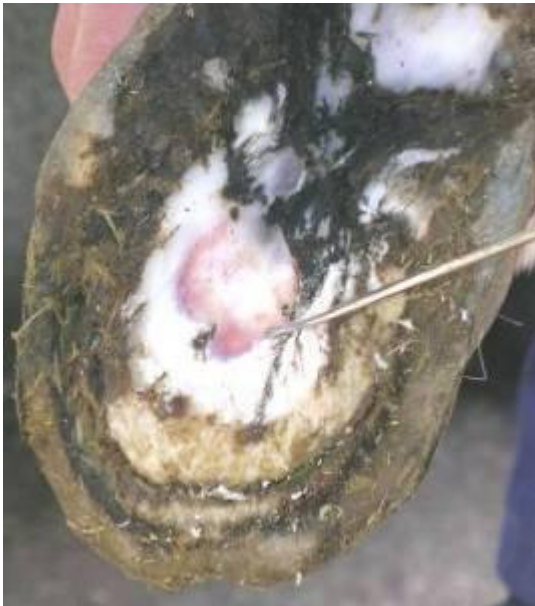

(“Sugardine” is made by mixing Povidine (Iodine) antiseptic solution with granulated sugar to a crumbly texture.)



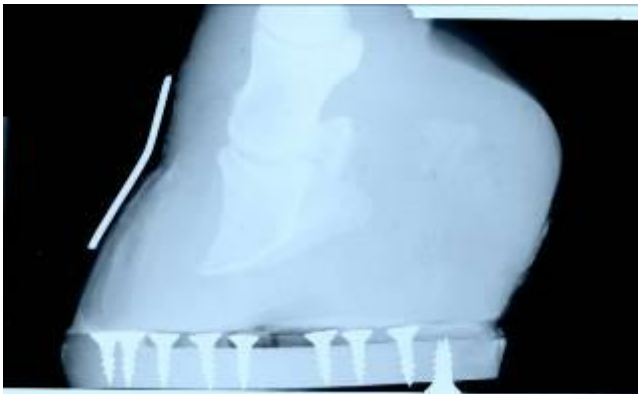
## The Laminitic Foot –Notes for Farriers

Trim every 6 – 10 weeks as required. Consider more frequent farriery if hoof growth accelerates post laminitis.

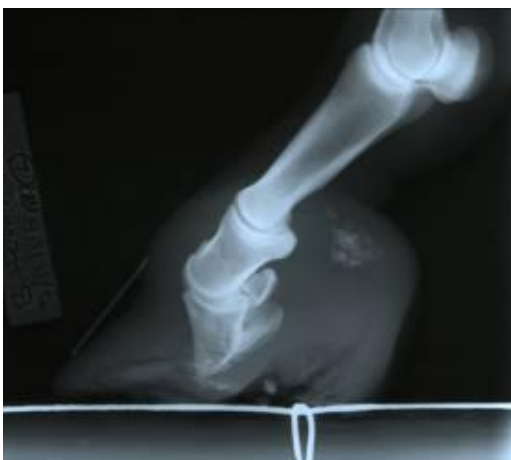

In some laminitic donkeys the sole may be too thin to trim. Use the thumb pressure test to feel the difference between old bruising and live blood supply, if in doubt, radiographs will help to determine the position and any changes to P3.

Frog supports & Heart-bar shoes are not appropriate for use on laminitic donkeys. They transfer weight to the point of the frog which is around 2cm behind the fulcrum of the P3. Pad the entire sole and foot with thick cotton wool and bandage.



In some cases of chronic laminitis, particularly where the soles are very thin, plastic shoes may be indicated to move weight bearing from the sole back to the walls. In these cases we advise consultation with a veterinary surgeon and the use of diagnostic X-rays as plastic shoes may not be appropriate for some severely laminitic / foundered donkeys (see pictures below).



## Plastic Shoes – Notes for Farriers

Plastic shoes which reduce weight-bearing on the sole by adding a rim of plastic “wall”, may be of help in chronic cases.



Trim and clean foot. Roughen surface of hoof wall with emery paper or decorators rubbing down pad (DIY supplies). Ensure that the indent or “divot” in the caudal wall area is not missed. The hoof must be dry.

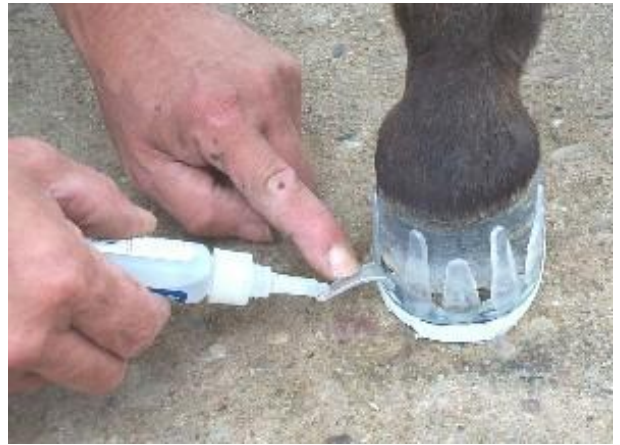Draw outline of hoof on base plate with marker - slightly ‘oversize’. Cut out with coping saw. Smooth edges of base plate with rasp. Roughen surface of base plate with dremel.



Fit cuff to base plate, you may have to cut tabs off of the cuff if foot is small. Stick cuff to base plate with superglue e.g. “Locktite 406”, press down until stuck.

Secure with self-tapping screws e.g. (POZI HP25 3.5 hardened steel), insert front screw first – make sure heads are flush. Roughen inside of cuff tabs with a dremel.





Fix shoe to hoof wall with superglue. This is only a temporary measure to keep shoe in place. Do not use excess glue. Start with both rear tabs with donkey non-weight bearing. Push base plate with hand. Put hoof back on the ground and secure cuff tabs with glue, start on the end of the cuff clip and allow glue to flow down, then press to stick.



To secure shoe apply resin e.g. "Bond N Flex" to the hoof wall between and over the tabs, smooth with a putty knife. It is important to "squirt" the mix gently as it should not get into the gap between sole and base plate.



When "butter" like consistency reached (3-4 minutes) smooth in around tabs. **(Wear gloves)**. In cooler weather it may take longer to "go off". Carry the cartridge in a back pocket for 10 minutes to warm before use.

Leave donkey tied up or held for about 10 minutes before walking. Do not allow hoof to become wet and avoid contact with bedding during this time.

After fitting the shoe there should be a gap between the sole plate and the sole of the hoof, this should be checked daily to make sure it remains clean.

Change shoes every 4 weeks, if donkey becomes lame, any existing lameness deteriorates or donkey is any discomfort remove shoes immediately.

To remove cut off clips with hoof knife, rasp off old resin.